

Efficacy of Surgical Management of Meralgia Paresthetica

Ahmed Saleh

Department of Neurosurgery,
Benha Faculty of Medicine, Benha University

ABSTRACT

Objective: This study was designed to evaluate the efficacy of surgical decompression in treatment of meralgia paresthetica. **Patients and Methods:** This study included 30 patients (18 females, 12 males) within age range of 24-62 years presented with meralgia paresthetica with mean duration of symptoms 29.3 ± 5.4 months. All the patients were subjected to conservative management for 6 months. 12 patients were not improved with conservative treatment. 9 patients (70%) underwent unilateral neurolysis of the lateral femoral cutaneous nerve (LFCN), whereas 3 patients (25%) underwent bilateral neurolysis of the LFCN. Surgical outcome was graded subjectively by each patient postoperatively based on 0-5 pain intensity scale. **Results:** The mean follow-up period was 14 months; range: 6-24 months. Surgical outcome was graded subjectively by each patient postoperatively based on 0-5 pain intensity scale; 5 patients (41.7%) improved completely; 2 patients (16.7%) significantly improved; 1 patient (8.3%) temporarily improved; 4 patients (33.3%) not improved, (Table 7). For the 4 (33.3%) patients who did not improve after surgical decompression, re-exploration with trans-section of the LFCN was done (1 case bilateral, 3 unilateral) & pain improved completely in all patients. **Conclusion:** It could be concluded that neurolysis of the LFCN is an effective treatment for meralgia paresthetica in properly selected patients & trans-section of the LFCN is indicated for patients who did not improve after surgical decompression.

Keywords: Neurolysis, lateral femoral cutaneous nerve, meralgia paresthetica.

INTRODUCTION

Meralgia paraesthetica is a clinical syndrome resulting from the entrapment of the lateral femoral cutaneous nerve (LFCN) of the thigh in the inguinal region¹⁻³. It is also known as Bernhardt-Roth syndrome, was first described in 1878^{1,4,5}.

It is characterized as being disagreeably numb or a burning, tingling or pricking sensation over the anterolateral aspect of one or rarely both thighs. It is commonly observed following chronic irritation of the nerve due to mechanical factors exerting a downward pull or traction on the inguinal ligament. Obesity, pulmonary obstructive disease with a chronic cough and anatomical variations in the course of the nerve are

common predisposing factors. The occurrence of meralgia paraesthetica following lumbar spine surgery is uncommon and there are few reports in the literature on this subject⁶.

Anatomy

The LFCN is primarily a sensory nerve but also includes efferent sympathetic fibers carrying vasomotor, pilomotor, and sudomotor impulses⁷. It is quite variable and may be derived from several different combinations of lumbar nerves, including L2 and L3, L1 and L2, L2 alone, and L3 alone⁸. The LFCN may be associated with the femoral nerve as it passes through the inguinal ligament or may anastomose with the femoral nerve distal to the inguinal ligament. Piersol⁹ reported that the LFCN may be partially or entirely derived from the adjacent

genitofemoral or femoral nerve, and Keegan and Holyoke¹⁰ noted this variation in 30% of their cadaver dissections. On occasion, the LFCN is absent and may be replaced by a branch of the ilioinguinal nerve⁸.

The LFCN passes behind the psoas muscle and runs beneath the iliac fascia as it crosses the surface of the iliacus muscle. As the nerve approaches the anterior superior iliac spine, it pierces the iliac fascia and exits through a fibrous tunnel into the thigh. Lee¹¹ noted that the nerve is vulnerable to pressure or stretching where it emerges beneath the psoas muscle, passes around the anterior superior iliac spine, courses through the fibrous canal of the fascia lata, and finally exits the fascia lata. The site at which the LFCN exits the pelvis varies, and symptoms of meralgia paresthetica have been reported with each of five known variants.

The LFCN is most frequently found passing through the split lateral attachment of the inguinal ligament. As the nerve curves medially and inferiorly around the anterior superior iliac spine, it may be subjected to repetitive trauma in this fibroosseous tunnel. Nathan¹² observed thickening of the LFCN at this level in 60% of his cadaver dissections and postulated that this was a direct response to chronic irritation.

The nerve may pass posterior to the inguinal ligament and anterior to a sharp ridge of iliacus fascia. Ghent¹³ noted that this variation may lead to a bowstring deformity of the nerve when

the patient is supine. Occasionally, the LFCN enters the thigh within or beneath the substance of the sartorius muscle. Stookey¹⁴ reported that in some instances the nerve passed through a shallow bony groove posterior to the sartorius. Ghent¹³ and Stookey¹⁴ both reported symptomatic patients with this variation.

Several cases have been reported in which the LFCN crosses over the iliac crest lateral and posterior to the anterior superior iliac spine. The nerve typically lies in a groove in the ilium and is subject to pressure from tight garments or belts¹³⁻¹⁴.

The nerve may exit the pelvis in multiple branches with entrapment of a single branch. Williams and Trzil⁴ reported displacement of the branches as much as 6 cm medial to the anterior superior iliac spine.

PATIENTS & METHODS

This prospective study was conducted at Neurosurgery department, Benha University Hospital. over a period of 2 years ,started April 2005 and comprised 30 patients (18 females, 12 males) within age range of 24-62 years presented with meralgia paresthetica with mean duration of symptoms 29.3 ± 5.4 months.

Etiologies included idiopathic causes, inguinal herniorrhaphy, external compression, diabetic neuropathy, Caesarean section and total abdominal hysterectomy (Table 1).

Table 1. Etiologies of meralgia paresthetica in the study group

Etiology	Number
Inguinal herniorrhaphy	8
External compression	3
Diabetic neuropathy	4
Total Abdominal hysterectomy	2
Caesarean section	1
Idiopathic causes	12

Inclusion criteria included the presence of: positive Tinel's sign next to the ASIS; presence of LFCN tenderness next to the ASIS; presence of paresthesias in the distribution of the LFCN. Spinal etiology for their pain was excluded by clinical examination, computed tomography or magnetic resonance imaging for suspected cases.

All the patients were subjected to conservative management for 6 months involving weight loss in obese patients, avoidance of abdominal courset and constricting garments, physical therapy, NSAID and anti-neuropathic drugs.

12 patients were not improved with conservative treatment, Further evaluation was done, included: history and physical examination; the presence of associated neuropathic groin, leg or back pain; patient's preoperative pain level. Pressure-Specified Sensory Device (PSSD) studies and nerve block by injecting a small amount of bupivacaine with epinephrine around the LFCN where it passed near the anterior superior iliac spine. The accuracy of the injection was confirmed by obtaining anterolateral thigh paresthesia, and in each case the symptoms were completely relieved for several hours.

9 patients (70%) underwent unilateral neurolysis of the LFCN, whereas 3 patients (25%) underwent bilateral neurolysis of the LFCN (Fig.1). Surgical outcome was graded

subjectively by each patient postoperatively based on 0-5 pain intensity scale. Interval from surgery to relief of pain; interval from surgery to improvement of thigh paresthesias; and patient's subjective level of satisfaction with surgery were estimated.

Patients were examined & asked to grade their outcome during follow-up at Neurosurgery outpatient clinic visits. Mean follow-up time was 14 months.

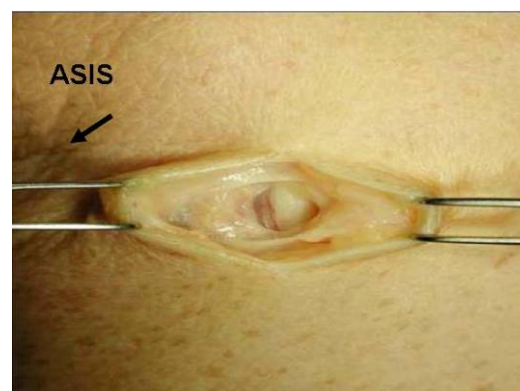


Fig. (1). Lateral femoral cutaneous nerve exposure (AsIs: Anterior Superior Iliac Spine)

RESULTS

The study comprised 30 patients; 18 females (60%) and 12 males (40%), (Table 2). Patients mean age was 46 ± 12.5 ; range: 24-62 years, Patients were presented with meralgia paresthetica with mean duration of symptoms 29.3 ± 5.4 months, (Table 3).

After conservative management for 6 months; 18 patients (60%) improved & 12 patients (40%) not improved, (Table 4).

The causes of meralgia paresthetica in the twelve patients who undergone surgical decompression were; 5 patients (41.7%) post inguinal hernia repair; 6 patients (50%) idiopathic & 1 patient (8.3%) post hysterectomy, (Table 5).

Unilateral decompression was done in 9 cases (75%); Bilateral decompression was done in 3 cases (25%), (Table 6).

Following surgery, preoperative pain level took an average of 2-4 weeks for relieve of incisional pain and tenderness over the LFCN to occur,

however relieve of paresthetica pain took 2 days to 6 months (with a median of 6 weeks) after surgery.

The mean follow-up period was 14 months; range: 6-24 months. Surgical outcome was graded subjectively by each patient postoperatively based on 0-5 pain intensity scale; 5 patients (41.7%) improved completely; 2 patients (16.7%) significant improved; 1 patient (8.3%) temporary improved; 4 patients (33.3%) not improved, (Table 7).

For the 4 (33.3%) patients who did not improve after surgical decompression, re-exploration with trans-section of the LFCN was done (1 case bilateral, 3 unilateral) & pain improved completely in all patients.

Table 2. Distribution of the study group according to sex

SEX	NO	%
Females	18	60.0
Males	12	40.0
Total	30	100.0

Table 3. Means \pm SD and range of age & duration of symptoms of the study cases

Variables	X \pm SD	Range
Age (years)	46 \pm 12.5	24-62
Duration of symptoms	29.3 \pm 5.4	21-38

Table 4. Distribution of the study group according to improvement with medical treatment

Cases	No	%
Improvement with medical treatment		
Improved	18	60.0
Not improved	12	40.0
Total	30	100.0

Table 5. Distribution of the surgical cases according to causes

Cases	No	%
Post inguinal hernia repair	5	41.7
Idiopathic	6	50.0
Post hysterectomy	1	8.3
Total	12	100.0

Table 6. Distribution of the study cases (12) according to surgery

SURGERY	NO	%
Unilateral	9	75.0
Bilateral	3	25.0
Total	12	100.0

Table 7. Scale for pain relief 1-5 .

Outcome	No	%
Grade 1 (poor)	4	33.4
Grade 2 (fair)	1	8.3
Grade 3 (good)	1	8.3
Grade 4 (very good)	1	8.3
Grade 5 (excellent)	5	41.7
Total	12	100.0

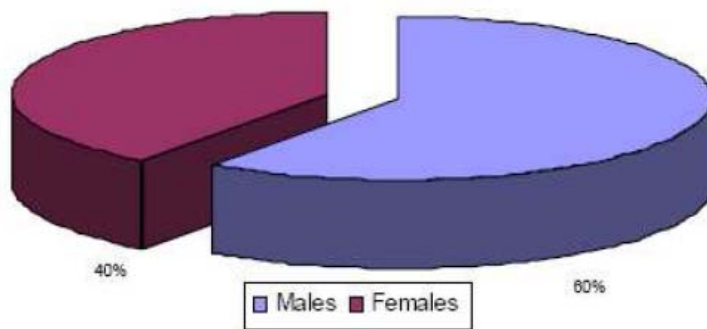


Fig.2.Distrubtion of the study group according to sex

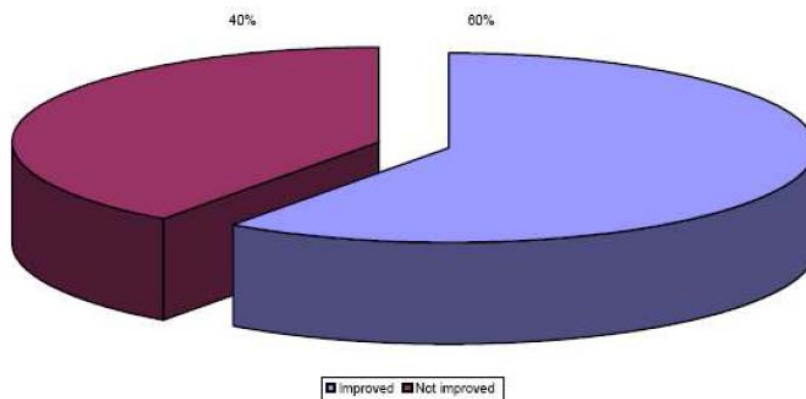


Fig. (3): Distribution of the study group according to improvement with medical treatment

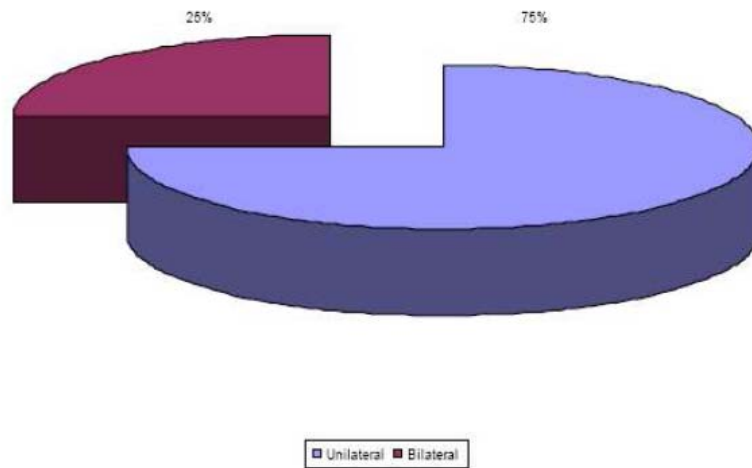


Fig. (4): Distribution of non-improved cases according to surgery

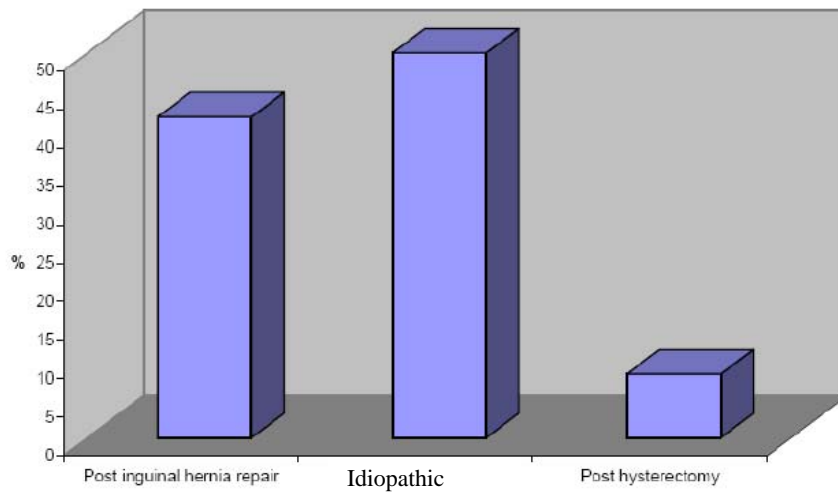


Fig. (5): Distribution of the surgical cases according to causes

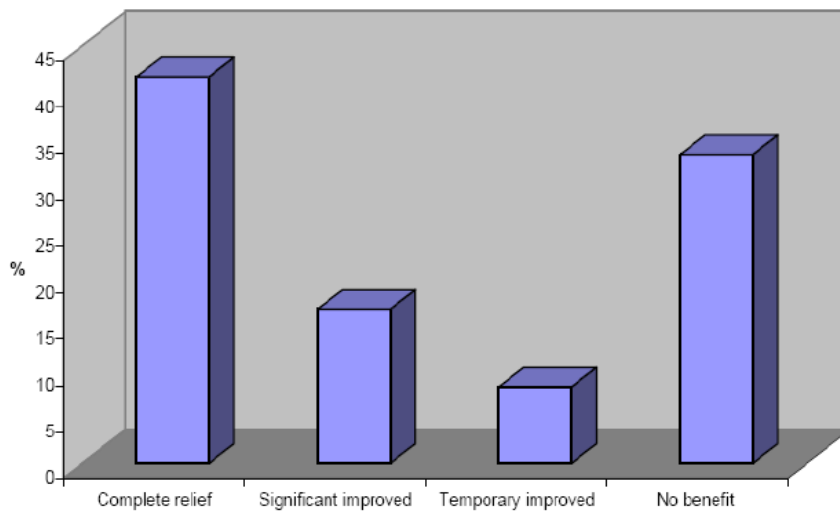


Fig. (6): Distribution of the study cases according to surgical decompression

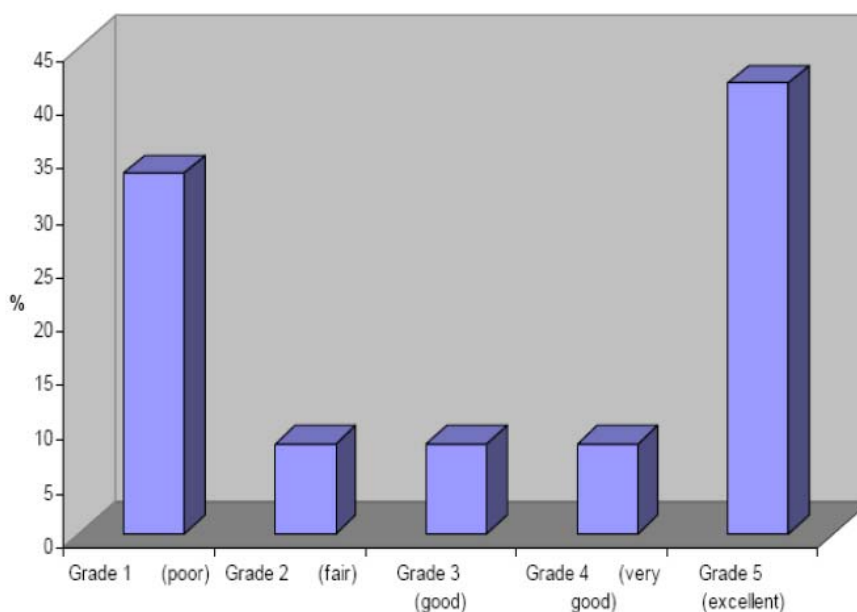


Fig. (7): Scale for pain relief (1-5)

DISCUSSION

As the LFCN exits the pelvis, it is subject to compression and stretching injuries by such conditions as obesity, pregnancy, ascites, tight garments, seat belts, braces, direct trauma, leg length changes, scoliosis, and muscle spasm⁴. It may also be injured by lower abdominal and pelvic incisions, such as for appendectomies¹⁵, iliac wing bone grafts¹⁶, and Chiari pelvic osteotomies¹⁷.

The LFCN typically separates into an anterior and a posterior branch several centimeters distal to the anterior superior iliac spine. Various authors in the past have postulated isolated involvement of either the anterior or posterior branch, based on the surface distribution of symptoms^{10,18}. Williams and Trzil⁴ have surgically confirmed that this can occur. Some variations in the surface distribution of symptoms are also likely due to variations in nerve root derivation.

Ecker and Woltman¹⁹, Stookey¹⁴, Aird²⁰, Brain²¹, Chhuttari et al²², Kitchen and Simpson²³, and Huddleson²⁴ all reported a male predominance. Rosenheck²⁵ noted an equal distribution between the sexes in his series, whereas King²⁶, Rhodes²⁷ and Williams and Trzil⁴ reported a female predominance. In the present series, 18 of the 30 patients were female.

The incidence of bilateral involvement was reported as 10% by Kitchen and Simpson²³, 15% by Chhuttari et al²², 20% by Ecker and Woltman¹⁹ and 50% by Rosenheck²⁵ and delson and Stevens²⁸. 3 cases of bilateral involvement (25%) was encountered in the present series.

Surgical treatment of meralgia paresthetica should be reserved only for those individuals who fail medical treatment; successful surgical treatment first begins with correct diagnosis¹. Compression of the LFCN can occur predominantly at three different sites: as the nerve exits the

spinal column; as the nerve courses along the pelvic wall; and as the nerve exits the pelvis to enter the thigh. Classically, meralgia paresthetica is caused by compression of the LFCN at the site where it exits the pelvis, but it is important to realize that other neuropathies may mimic meralgia paresthetica. The differential diagnosis for anterolateral thigh pain and paresthesia is varied and includes lumbar radiculopathy; lumbar facet syndrome; increased retroperitoneal pressure resulting from tumor, hemorrhage, or abscess; mononeuritis multiplex; diabetic lumbosacral plexopathy; and lumbar spondylolysis and spondylolisthesis¹.

The most likely pathology to mimic meralgia paresthetica is lumbar radiculopathy^{4,29}. However, meralgia paresthetica produces no motor deficit as there is a purely sensory nerve involved, and there should be no lumbar pain, sciatic notch tenderness, or positive straight-leg raising sign⁴. Moreover, pain or presence of a positive Tinel's sign over the ASIS additionally support the diagnosis of meralgia paresthetica^{4,30}.

In order to objectively document LFCN neuropathy, it is recommended that surgical candidates have both the affected and contralateral nerves tested with the Pressure-Specified Sensory Device, which is a noninvasive and painless computer-assisted method of neurosensory testing. In their study, Coert and Dellon³⁰ demonstrated that PSSD is an effective means of testing for neuropathy and is superior to more traditional forms of electrodiagnostic studies.

Although Eerten et al³¹ found resection to be superior to neurolysis, our results from 12 consecutive procedures show that neurolysis has a success rate of 58.3%. Eerten et al³¹

stated that neurolysis should, in theory, relieve symptoms more frequently than it does. Release of the nerve entrapment is effective treatment for other nerve compression syndromes, yet seems to be less effective for meralgia paresthetica.

In our study 4 (33.3%) patients who did not improve after surgical decompression, re-exploration with trans-section of the LFCN was done (1 case bilateral, 3 unilateral) & pain improved completely in all patients. This agrees with Eerten et al³¹ who suggested that intraneural changes occur such that a painful neuropathy predominates. In this circumstance, this "pain generator" is unresponsive to neurolysis, and stated that resection is the most efficacious treatment, with patients preferring the hypoesthesia to the hyperesthesia.

Patients who fail to respond to conservative therapy should be considered for surgery, but there is no consensus as to the best surgical treatment. King²⁶ and Williams and Trzil⁴ recommended resection. Stookey¹⁴ advised transecting the nerve. Ghent¹³ advocated excision of the posterior slip of the inguinal ligament to decompress the nerve, or transection of the nerve when this was impossible. Edelson and Stevens²⁸ recommended decompression in their pediatric patients, whereas Macnichol and Thompson³² concluded that decompression was effective in less than half of their adult patients. Lee¹⁰ and Mack³³ transposed the nerve laterally by cutting a slot in the iliac wing. Keegan and Holyoke¹¹ divided the posterior slip of the inguinal ligament and transposed the nerve medially. Aldrich and Van den Heever³⁴ advocated neurolysis with or without transposition and advised against transection. Williams and

Trzil⁴ reported on 24 patients treated with nerve resection. The patients ranged in age from 19 to 68 years, and follow-up was 4 to 25 years. Twenty-three of the patients had sustained satisfactory relief.

Edelson and Stevens²⁸ reported long-term follow-up of 21 cases of meralgia paresthetica in 13 patients age 1 to 17 years. Patients were treated with decompression, resulting in complete relief in 14 cases and significant improvement in 5. Two patients initially had complete relief but subsequently developed recurrent symptoms.

When resection is indicated, the LFCN should be divided several centimeters posterior to the anterior superior iliac spine. This has the advantage of avoiding any scar tissue from previous decompression surgery and provides a single larger nerve for dissection. In addition, this places the transected nerve trunk in a protected area that is not likely to be stimulated.

CONCLUSION

It could be concluded that neurolysis of the LFCN is an effective treatment for meralgia paresthetica in properly selected patients & transection of the LFCN is indicated for patients who did not improve after surgical decompression.

REFERENCES

1. **Nahabedian MY, Dellon AL.** Meralgia paresthetica: etiology, diagnosis, and outcome of surgical decompression. *Ann Plast Surg* 1995;35:590-4.
2. **Holanda MM, Meira UM, Magalhaes FN, da Silva JA.** Surgical treatment of meralgia paresthetica: case report. *Arq Neuropsiquiatr* 2003;61:288-90.
3. **Grossman MG, Ducey SA, Nadler S S, Levy AS.** Meralgia paresthetica: diagnosis and treatment. *J Am Acad Orthop Surg* 2001;9:336-44.
4. **Williams PH, Trzil KP.** Management of meralgia paresthetica. *J Neurosurg* 1991;74:76-80.
5. **Aszmann OC, Dellon ES, Dellon AL.** Anatomical course of the lateral femoral cutaneous nerve and its susceptibility to compression and injury. *Plast Reconstr Surg* 1997;100:600-604.
6. **Mirovsky Y, Neuwirth M.** Injuries to the lateral femoral cutaneous nerve during spine surgery. *Spine* 2000;25:1266-9.
7. **Reichert FL.** Meralgia paresthetica; a form of causalgia relieved by interruption of the sympathetic fibers. *Surg Clin North Am* 1933; 13:1443.
8. **Sunderland S.** Nerves and Nerve Injuries. Edinburgh: E & S Livingstone, Ltd; 1968.
9. **Piersol GA.** Human Anatomy, 9th ed. Philadelphia: JB Lippincott; 1930:2104.
10. **Lee FC.** Meralgia paresthetica. *Int Clin* 1936; 1:210.
11. **Keegan JJ, Holyoke EA.** Meralgia paresthetica—an anatomical and surgical study. *J Neurosurg* 1962; 13:341.
12. **Nathan H.** Gangliform enlargement on the lateral cutaneous nerve of the thigh. *J Neurosurg* 1960; 17:843.
13. **Ghent WR.** Further studies on meralgia paresthetica. *Can Med J* 1961; 85:871.
14. **Stookey B.** Meralgia paresthetica: etiology and surgical treatment. *JAMA* 1928; 90:1705.

15. **Pecina M, Kimpotic-Nemanic J, Markiewitz A.** Tunnel Syndromes. Boca Raton: CRC Press; 1991:105–111.
 16. **Flowers RS.** Meralgia paresthetica - a clue to retroperitoneal malignant tumor. *Am J Surg* 1968; 116:89.
 17. **Massey EW.** Meralgia paresthetica secondary to trauma of bone graft. *J Trauma* 1980; 20:342.
 18. **Arregui ME, Navarrete JL, Davis CJ.** Laparoscopic preperitoneal repair of inguinofemoral hernias with large prostheses. Presented at 2nd International Minimal Access Surgery Symposium, 1992.
 19. **Ecker AD, Woltman HW.** Meralgia paresthetica—a report of one hundred and fifty cases. *JAMA* 1938; 110:1650.
 20. **Aird I.** A Companion in Surgical Studies. Edinburgh: E & S Livingston, Ltd.; 1949.
 21. **Brain RW.** Diseases of the Nervous System. London: Oxford University Press; 1977:912.
 22. **Chhuttari PN, Chanla LS, Sharma TD.** Meralgia paresthetica. *Acta Neurol Scand* 1966; 42:483–490.
 23. **Kitchen D, Simpson J.** Meralgia paresthetica, a review of sixty-seven patients. *Acta Neurol Scand* 1972; 48:547–555.
 24. **Huddleson JH.** Meralgia paresthetica. *Am J Med Soc* 1928; 175:823.
 25. **Rosenheck C.** Meralgia paresthetica - its relation to osteoarthritis of the spinal vertebrae. *JAMA* 1925; 85:416.
 26. **King BB.** Meralgia paresthetica - report of five cases. *Am J Surg* 1941; 52:364.
 27. **Rhodes P.** Meralgia paresthetica in pregnancy. *Lancet* 1957; 273:831.
 28. **Edelson R, Stevens P.** Meralgia paresthetica in children. *J Bone Joint Surg [Am]* 1994; 76:993–999.
 29. **Lee CH, Dellon AL.** Surgical management of groin pain of neural origin. *J Am Coll Surg* 2000; 191:137–142.
 30. **Coert JH, Dellon AL.** Documenting neuropathy of the lateral femoral cutaneous nerve using the Pressure-Specified Sensory Testing device. *Ann Plast Surg* 2003;50:373–377.
 31. **Eerten PV, Polder TW, Broere CA.** Operative treatment of meralgia paresthetica: transection versus neurolysis. *Neurosurgery* 1995; 37:63–65.
 32. **Macnichol MF, Thompson WJ.** Idiopathic meralgia paresthetica. *Clin Orthop* 1990; 254:270–274.
 33. **Mack WW.** Meralgia paresthetica. New causal observations. *West J Surg Obstet Gynecol* 1946; 54:390.
 34. **Aldrich EF, Van den Heever CM.** Suprainguinal ligament approach for surgical treatment of meralgia paresthetica. *J Neurosurg* 1989; 70:492–494.
-