

Pedicle Instrumentation Failure in Thoracolumbar Fixation

*Mohamed Lotfy, **Nasser M. Sayed Ahmed, **Alaa A. Farag,
*Walid Raafat **Walid A. Badawy, **Hossam Ibrahim,
**Islam Abou El Fotouh, **Ahmed Saleh

Department of Neurosurgery, *Cairo University, **Benha University

ABSTRACT

Objective: The authors reviewed factors related to the surgical techniques resulting in failure of the construct of the internal fixation of thoracolumbar fractures through transpedicular screw systems and how to be avoided. **Patients and Methods:** The authors reviewed 280 consecutive patients with traumatic thoracolumbar fractures who underwent spinal surgical fixation with short segment transpedicular screw instrumentation at three institutions, between January 1997 and June 2005. All patients in this series were due to high-energy trauma. Among this series, 30 patients had a construct failure attributed to surgical technique causes. Clinical evaluation of the patients was performed on admission and at post-operative period using ASIA scale. All patients were radiologically investigated by plain X-rays and computerized tomographic (CT) scan spine on admission and occasionally MRI and 3D CT scan of the spine when required. The patients were followed up as regard to clinical and radiological evidences of construct failure. **Results:** Thirty patients out of 280 patients with post-traumatic thoracolumbar injuries had construct failures. Main clinical presentation of construct failure was severe pain and inability to walk at post-operative period. Radiologically there was progressive spinal deformity with implant failures. The locations of the fractures in order of frequency were as follows: L-1 in 18 cases, L-2 in 7 cases, T-12 in 5 cases. The construct failure was in the form of screws malposition in 13 patients, screws breakage in 10 patients, screw/rod dislodgement in 3 patients, disengaged screw's cup in 2 patients, and broken rods in 2 patients. **Conclusion:** Great attention must be directed to maintain the sagittal and coronal balances of the spine over the sacrum through reconstruction of comminuted anterior vertebral column, and appropriate distraction of the construct. In spite of routine use of pedicle screws, it has not been free of complications. The majority of construct failures is not actually device failures but instead is surgical technique causes.

INTRODUCTION

A traumatic fracture of the spine is a serious medical condition that can have a major impact on the quality of life of the patient. The management of traumatic fractures of the thoracolumbar spine remains controversial. A large number of publications, describing various surgical techniques for the reduction and fixation of spinal fractures, without a consensus on the optimal treatment. In general, surgical treatment of thoracolumbar fractures is deemed necessary if the biomechanical stability of the spine is severely compromised and/or if a neurologic deficit is

imminent or already present. Segmental fixation systems decrease the need for postoperative immobilization and bracing and facilitate early rehabilitation and ambulation^[8,13,16,19,32&33].

Short-segment pedicle screw instrumentation is a well described technique to reduce and stabilize thoracolumbar fractures. It has been increasingly used over the past decade, with numerous reports of good clinical results. It is a relatively easy procedure but can indirectly reduce a fractured vertebral body, and the means of augmenting the anterior column are limited^[6,7].

Compared with other fixation systems, segmental spinal fixation through transpedicular instrumentation provides the most biomechanically rigid restraint to spinal motion in flexion, extension, and torsion^[32,35,36,38]. Because pedicle screw systems generally require fewer instrumented segments, they are advantageous in preserving motion segments, which is particularly important in the mobile lumbar spine. These advantages have made transpedicular fixation a mainstay of treatment for thoracolumbar fixation procedures. Despite these advantages, transpedicular fixation is associated with risks of screw breakage; screw/rod disconnection; pseudoarthrosis; nerve root injury, dural laceration, and pedicle fracture during screw insertion^[5,14,15,18&27].

In unstable burst-type fractures, the spinal deformity consists of a loss of vertebral body height, kyphotic angulation, and retropulsion of bone into the spinal canal. Posterior instrumentation restores vertebral body height via distraction forces. Additionally, the anterior and middle columns are restored to normal length during correction of the kyphosis. The spinal column assumes the contour of the rods, resulting in correction of the kyphotic deformity^[11,21].

Hardware failure and loss of reduction after posterior short-segment instrumentation are complications caused by insufficiency of anterior column support. This is due to migration of disc tissue through the endplate into the fractured vertebral body that cannot be restored with posterior instrumentation^[1,20,22].

The construct failures might be occurred due to multiple factors related to fixation devices (hardware), patient's conditions (age, osteoporosis), and surgeon-related pitfalls (surgical techniques). In this study we

spotlighted on the construct failures related to surgical techniques, and how to be avoided

PATIENTS & METHODS

This is a retrospective analysis of the medical records at the neurosurgical departments at Benha University Hospital, Nasser Institute Hospital (Egypt), and King Fahd Hospital (Saudi Arabia), for patients underwent surgical treatment for post-traumatic thoracolumbar injury. Between January 1997 and June 2005, 280 consecutively treated patients with short segmental transpedicular instrumentations were enrolled in this study to determine the surgeon-related pitfalls which predispose for construct failure.

Patients' population

Inclusion criteria included all patients in whom short segmental instrumentation was used for treatment of traumatic thoracolumbar fractures. Criteria for exclusion were: 1- Non-traumatic thoracolumbar fractures. 2- Patients who had evidence of osteoporosis. 3- Patients who did not applied thoracolumbar bracing post-operatively. 4- Patients who underwent an instrumentation procedure and then sustained to another insult of trauma. 5- Patients with follow up period less than 6 months.

Out Of the 280 patients there were 190 males and 90 females with a mean age of 35.6 years (range 16--65 years). All patients in this series were due to high-energy trauma. The mechanism of injury was, 168 cases (60%) injured in RTA, 84 cases (30%) fell from height, and 28 cases (10%) pedestrians struck by a motor vehicle.

At the time of admission the initial neurological assessment was done according to ASIA scale, normal motor strength was demonstrated (type E) in 4 patients, mild motor weakness (type

D) in 20, incomplete spinal cord or cauda equina injury with less than antigravity strength (type C) in one patient, and complete paraplegia (type A) in 5 patients (table 2).

The location of the fractures in order of frequency was as follows: *L-1* level in 18 (60%) of the patients, *L-2* level in 7 (23.3%) of the patients, *T-12* level in 5 (16.7%) of the patients, (table 3).

The distribution of patients including in this study along the specified time per year was demonstrated in fig.7 and showed the relation between the numbers of failed construct with the numbers of operated patients by the same technique.

Radiological assessment

Anteroposterior and lateral radiographs are obtained in all patients. If one spinal fracture is detected, total spine X-ray was taken, because noncontiguous spine fractures occur in 10% to 30% of patients^[16].

CT scan was done in all patients; CT has enhanced the understanding of mechanisms of neurologic injury and fracture morphology. To allow accurate fracture classification and to help direct treatment, we recommended 3D CT examination.

Magnetic resonance imaging (MRI) requested to demonstrate spinal cord pathology and the presence of neural compression, other soft tissue injuries and the state of the intervertebral disc can be identified. MRI can predict neurologic recovery in some cases based on T2 weighted images. Also, MRI can be used to assess the status of the posterior ligamentous complex.

Classification of thoracolumbar fracture:

The McAfee system identifies six fracture types based on CT scan findings is currently the best classification (Table 1).

Indications for Surgical Treatment:

Indications for surgical treatment included: (1) Two or three column fractures or fracture/dislocations; with or without neurological deficits (2) Stable fractures with incomplete neurologic deficits, spinal deformity or canal compromise.

Timing of surgery:

Patients with incomplete or complete neurological deficits required surgical decompression were treated as soon as possible. Patients who were neurologically intact with compromised anterior vertebral column we prefer to be preformed within first two days to achieve optimum re-expansion of the collapsed vertebral body.

Operative technique:

The patients were treated with short segmental instrumentation consisting of pedicle screws applied immediately above and below the fractured level. All patients were operated upon on prone position laying on a transverse chest and pelvic rolls, which increase lordosis, to enhance reduction of the deformity. Decortication of the facet joint was performed -in some patients- to identify the proper entry point and make the surface of the joint flat. K-wire (Kirschner) was placed and lateral X-ray taken. Spinal laminectomy opposite the compromised neural canal was performed, when required for neural decompression and/or dural repair. Neurophysiological monitoring was not conducted during the placement of instrumentation. Different transpedicular screws systems were used in this series of patients. Variable-angle –polyaxial-pedicle screws have been used and preferred to overcome some limitations of the standard mono-axial screws.

Follow-Up Studies:

All patients were mobilized as soon as possible. Each patient wore an

external orthosis (lumbosacral belt) for 6 to 8 weeks. Serial postoperative radiographs were obtained on follow-up clinic visits at 2 weeks, 6 weeks, 3 months, 6 months, and 1 year.

RESULTS

Thirty patients with construct failure were identified in 280 consecutive patients in whom short segment transpedicular instrumentation was placed. The causes of failure were attributed to poor surgical techniques in our opinion resulting in an overall failure incidence of 10.7%. There were 25 men, and 5 women with the mean age of 25.6 years (range 18-40 years). On admission 4 (13.3%) patients were neurologically intact grade E according to ASIA scale, 20 (66.6%) patients had mild neurological deficits grade D, one (3.3%) patient with grade C, and 5 (16.6%) patients with complete motor and sensory affections grade A. All the patients with partial neurological deficits showed marked improvement post-operatively and ambulate independently without assistant (table 2).

Five patients (16.6%) had wedge fracture, 21 patients (70%) with unstable burst fractures, and four patients (13.4%) with flexion-distraction spinal injury according to

McAfee classification (table 1). All the patients in current group showed some degree of spinal canal encroachment by retropulsed bony elements.

Surgical internal fixation was performed at one level in 230 patients, and two levels in 50 patients. A total of 1320 screws were inserted at 280 patients. 46 screws (3.5%) were failed either in the form of malposition -29 screws- in 13 patients (43.3%) (fig.1,2), or broken -17 screws- in 10 patients (33.3%) (fig.3). The cups of screws disengaged from the head in two patients (6.6%) (fig.6), while we have 4 broken rods in two patients (6.6%) (fig.5), and rods dislodgement from the head of screws in three patients (10%) (fig.4) (table 4).

26 patients (86.6%) underwent posterior decompression in the form of wide laminectomy and medial facetectomy in some cases. In 15 patients (50%) multiple levels were included. No intra-operative complications were noticed. All patients improved as regard to axial pain immediately post-operative, but as the construct failed the pain returned again and it was the main complain. No patient in the current group showed post-operative deterioration for their neurological state, instead, all the patients with mild weakness improved post-operatively.

Table (1): McAfee classification of thoracolumbar fractures and construct failure

Type of fracture	Patients with Construct failure	Total No of patients
Wedge-compression	5	75
Stable burst	--	--
Unstable burst	21	135
Chance	--	16
Flexion-distraction	4	42
Translational	--	12
Total	30	280

Table (2): Clinical presentation and construct failure

ASIA scale	Patients with Construct failure	Total No of patients
Type A	5	80
Type B	--	10
Type C	1	27
Type D	20	108
Type E	4	55
Total	30	280

Table (3): Type of spinal fractures and fracture level

Fracture level Type of fracture	D10		D11		D12		L1		L2	
	N	F	N	F	N	F	N	F	N	F
Type of fracture	N	F	N	F	N	F	N	F	N	F
Wedge-compression	--	--	3	--	14	1	49	3	10	1
Stable burst	--	--	--	--	--	--	--	--	--	--
Unstable burst	1	--	5	--	6	2	85	13	23	6
Chance	2	--	5	--	10	--	6	--	--	--
Flexion-distraction	4	--	6	--	27	2	6	2	2	---
Translational	4	--	8	--	4	--	--	--	--	--
Total	11	---	27	---	61	5	146	18	35	7

N = Number of patients

F = Failure of construct

Table (4): Type of construct failures

Type of construct failure	Total No.	No. of patients	One level	Multiple levels
Screw malposition	29	13	8	5
broken screw	17	10	6	4
Dislodged of rods	3	3	1	2
Loosing of the screw's cup	2	2	0	2
broken rod	3	2	0	2
Total		30	15	15

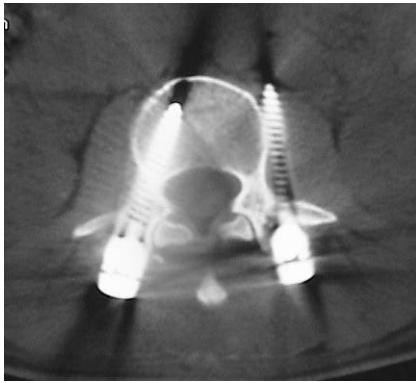


Fig 1: Screw outside the pedicle and vertebral body

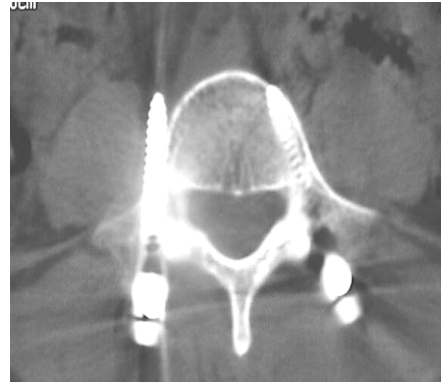

Fig 2: Screw penetrate the lateral side of the pedicle and outside the vertebral body

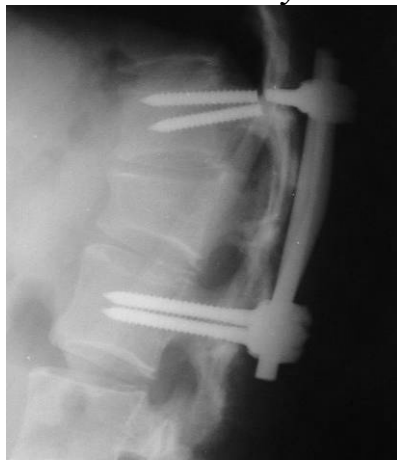

Fig 3: Bilateral broken screws with progressive kyphosis

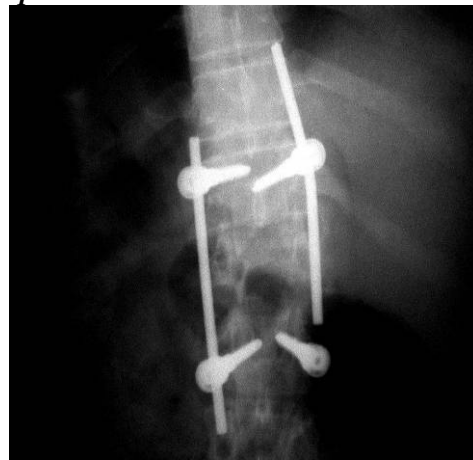

Fig 4: Rod dislodges from the head of the screw

DISCUSSION

The technique of posterior instrumentation for thoracolumbar fractures had been studied extensively. Various methods have been described for identifying the pedicle and placing the pedicle screws. Basic steps include: cleaning the soft issues, exposing the cancellous bone of the pedicle by decortications at the intersection of the base of the facet and the middle of the transverse process, probing the pedicle, tapping the pedicle and placing the screw. In the lower thoracic levels, screw placement with a straight forward direction may be safe. The incidence of pedicle wall violation was significantly reduced when screws were placed using open-lamina

technique through partial laminectomy^[3,14,23&31].

In the original technique described by Roy-Camille^[28], the entrance point for screw insertion was situated in the inter section between a vertical line passing through the middle of the inferior facet and a transverse line passing through the middle of the transverse process. The direction of the screw was perpendicular to the posterior plane of the vertebra and straight forward. No information on pedicle wall violation was documented by Roy-Camille. Verlaan et al.^[33] were the first to evaluate the feasibility of Roy-Camille technique. They observe higher percentage of lateral (31.6%) and inferior (11.6%) wall perforation.

Routine use of pedicle screw has not been free of complications^[26]. The rate of screw misplacement has ranged from 10 – 25% and cortical violation up to 50% in some reports^[3]. The frequency of screw breakage ranged from 2.6 to 9%. Screw pulls out and screw connector disengagements have been reported both in vitro testing and in vivo. The variable-angle screws are most useful in multilevel constructs in which several screw/rod connections are necessary. In this regard, there is a greater "margin of safety" in both the mediolateral and sagittal dimensions. The need for rod contouring is lessened, and each screw may be placed on an axis parallel to the superior endplate, reducing the chance of construct failures^[30].

Anterior column support is often insufficient in burst fractures of the vertebral body, and should be restored because a recurrent kyphosis, even neurological deficit, could otherwise develop. With balloon vertebroplasty, fractured endplates can be reduced directly and the intravertebral defect can be filled with methyl methacrylate^[34]. In combination with pedicle-screw instrumentation, used for anatomical alignment and indirect reduction, fracture stabilization and anterior column augmentation can be achieved with a posterior approach only. It was concluded that both methyl methacrylate, and calcium phosphate cement can safely be used as bone void fillers, but the latter is preferred in young patients due to its superior biocompatibility^[24,25].

Complications in this study group occurred early in our experience and were due to pitfalls in surgical techniques such as: missed probing the pedicle to verify the 4 walls of the pedicle, and not using 2 plane image guided to make sure correct placement of screws. Handling of the implants was very important to reduce the

incidence of screw/rod disengagement, and loosed screw's cup. While negligence of the competent of the anterior vertebral column especially in cases of burst and severe wedge fractures leading to progressive spinal deformity and failure of constructs. At the last cases we start to do transpedicular vertebroplasty with methyl methacrylate to restore and support the anterior column with promising results.

In our series, two patients had broken rods with the explanation of marked torsional stiffness of the implants due to using of multiple transverse connectors. Wood and colleagues^[37] who demonstrated that, the pedicle screws increased torsional stiffness when placed at the distal end of the constructs implanted for deformity correction.

Edwards et al.^[9] found excellent maintenance of alignment in terms of kyphosis, vertebral body height, and translation in their review of 122 patients. The spinal canal area was improved by 32% (from 55% patency to 87%) if the rod-sleeve construct was inserted within 2 days of injury. Between 3 and 14 days, they found a 23% improvement in spinal canal area (range, 53% to 76%). Little improvement was found with surgery after 14 days. In our study we advised early surgical correction of spinal deformity, our patients were operated within first two days post-traumatic with good results as regard to re-expansion of the collapsed vertebral body and angle of kyphosis. Short segment fixation using Cotrel-Dubousset (CD) instrumentation has had poor outcome as reported by McLain et al.^[22], they reviewed 19 patients and found vertebral collapse, vertebral translation, or hardware failure in 10 patients. The primary cause for failure was attributed to the fixation device. Good outcome studies using a hybrid

technique pitfalls, so a learning curve must be continued for spinal surgeons.

CONCLUSION

Short-segment pedicle screw fixation is a common and relatively simple method for treating thoracolumbar fracture. However, the posterior approach has some limitations, so training on the other alternative approaches is a must; specially with comminuted anterior vertebral column with anterior encroachment on the neural canal. Also, it must be performed within the first two days of trauma to achieve optimum re-expansion of the collapsed vertebral body.

So, Great attention must be directed to maintain the coronal and sagittal balance of the fractured spine by the proper distraction of the implant, and early reconstruction of the comminuted anterior column. However, failure to support the anterior spinal column after posterior correction and instrumentation is the main factor in construct failure.

Proper insertion of transpedicular screws is not depend only on the experience of the surgeon but also on the availability of suitable image monitoring to avoid malposition of the screws. Proper application of the rods over the screw head in a straight perpendicular angle and applied the screw's cup in correct mechanical way is necessary. The uses of variable-angle-polyaxial screws minimize the need for rod contouring, avoids pre-stress load applied on the construct, and reduce early construct failure.

The additional instrumentations like transverse connectors provide more rigidity and redistributes of the loading weight over the implants.

The spinal implant failures are not only device-failure but also surgical

REFERENCES

1. **Aebi M, Thalgott JS, Webb JK:** Modular stabilization system: the universal spine system, in Aebi M, Thalgott JS, Webb JK (eds): AO ASIF Principles in Spine Surgery. Berlin:Springer-Verlag, pp 123-196, 1998.
2. **Arnold P M, Strang R D, and Roussel D.** Efficacy of variable-angle screws in transpedicular fixation *Neurosurg Focus* 7 (6):Article 1, 1999.
3. **Benzel EC.** Short-segment compression instrumentation for selected thoracic and lumbar spine fractures: the short-rod/two-claw technique. *J Neurosurg.* 79: 335-340, 1993.
4. **Castro WH, Halm H, Jerosch J, Malms J, Steinbeck J, Blasius S.** Accuracy of pedicle screw placement in lumbar vertebra. *Spine* 11:1320-1324, 1996.
5. **Cresswell TR, Marshall PD, Smith RB.** Mechanical stability of the AO internal spinal fixation system compared with that of the Hartshill rectangle and sublaminar wiring in the management of unstable burst fractures of the thoracic and lumbar spine. *Spine* 23:111-115, 1998.
6. **Davne SH, Myers DL:** Complications of lumbar spinal fusion with transpedicular instrumentation. *Spine* 17 (Suppl 6):S184-S189, 1992.
7. **De Peretti F, Hovorka I, Cambas PM, et al.** Short device fixation and early mobilization for burst fractures of the thoracolumbar junction. *Eur Spine J.* 5: 112-120, 1996.

8. **Dick W:** The "fixateur interne" as a versatile implant for spine surgery. *Spine* 12: 882-899, 1987.
 9. **Dickman CA, Yahiro MA, Lu HT, et al.** Surgical treatment alternatives for fixation of unstable fractures of the thoracic and lumbar spine: a meta-analysis. *Spine*. 19 (suppl): 2266-2273, 1994.
 10. **Edwards CC, Levine AM.** Early rod-sleeve stabilization of the injured thoracic and lumbar spine. *Orthop Clin North Am.* 17: 121-145, 1986.
 11. **Esses SI, Botsford DJ, Kostuik JP.** Evaluation of surgical treatment for burst fractures. *Spine*. 15: 667-673, 1990.
 12. **Esses SI, Sachs BL, Dreyzin V:** Complications associated with the technique of pedicle screw fixation. A selected survey of ABS members. *Spine* 18:2231-2239, 1993.
 13. **Gertzbein SD, Robbins SE.** Accuracy of pedicular screw placement in vivo. *Spine* 1:11-14, 1990.
 14. **Glassman SD, Dimar JR, Puno RM, et al:** Salvage of instrumented lumbar fusions complicated by surgical wound infection. *Spine* 21:2163-2169, 1996.
 15. **Hitchon PW, Torner JC, Haddad SF, et al.** Management options in thoracolumbar burst fractures. *Surg Neurol.* 49: 619-626, 1998.
 16. **Knop C, Blauth M, Bühren V, et al.** Surgical treatment of injuries of the thoracolumbar transition: 3. Follow-up examination. Results of a prospective multi-center study by the Spinal Study Group of the German Society of Trauma Surgery. *Unfallchirurg.* 104: 583-600, 2001.
 17. **Knop C, Bastian L, Lange U, et al.** Complications in surgical treatment of thoracolumbar injuries. *Eur Spine J* 11:214-26, 2002.
 18. **Kraemer WJ, Schemitsch EH, Lever J, et al.** Functional outcome of thoracolumbar burst fractures without neurological deficit. *J Orthop Trauma* 10:541-544, 1996.
 19. **Leferink VJ, Zimmerman KW, Veldhuis EF, et al.** Thoracolumbar spinal fractures: radiological results of transpedicular fixation combined with transpedicular cancellous bone graft and posterior fusion in 183 patients. *Eur Spine J.* 10: 517-523, 2001.
 20. **Lesoin F, Bouasakao N, Cama A, et al.** Posttraumatic fixation of the thoracolumbar spine using Roy-Camille plates. *Surg Neurol.* 18: 167-173, 1982.
 21. **McAfee PC, Yuan HA, Lasda NA.** The unstable burst fracture. *Spine.* 7: 365-373, 1982.
 22. **McLain RF, Sparling E, Benson DR.** Early failure of short-segment pedicle instrumentation for thoracolumbar fractures: a preliminary report. *J Bone Joint Surg Am.* 75: 162-167, 1993.
 23. **Merloz P, Tonetti J, Eid A, et al.** Computer assisted spine surgery. *Clin orthop* 337:86-96, 1997.
 24. **Mermelstein LE, McLain RF, Yerby SA.** Reinforcement of thoracolumbar burst fractures with calcium phosphate cement. A biomechanical study. *Spine* 23:664-70, 1998.
 25. **Parker JW, Lane JR, Karaikovic EE, et al.** Successful short-segment instrumentation and fusion for thoracolumbar spine fractures: a consecutive 4 1/2-year series. *Spine* 25:1157-70, 2000.
 26. **Ramieri A, Domenicucci M, Passacantilli E, et al.** The results of the surgical and conservative treatment of non-neurologic comminuted thoracolumbar
-

- fractures. *Chir Organi Mov.* 85: 129-135, 2000.
- 27. Rehtine GR Jr, Cahill D, Chrin AM:** Treatment of thoracolumbar trauma: comparison of complications of operative versus nonoperative treatment. *J Spinal Disord* 12:406-409, 1999.
- 28. Roy-Camille R.** Osteosynthese du rachis dorsal, lombaire et lombosacré par plaques métalliques vissées dans les pédicules vertébraux et les apophyses articulaires. *Presse Med* 78:1447, 1970.
- 29. Stancic MF, Gregorovic E, Nozica E, et al.** Anterior decompression and fixation versus posterior reposition and semirigid fixation in the treatment of unstable burst thoracolumbar fracture: prospective clinical trial. *Croat Med J.* 42: 49-53, 2001.
- 30. Steffee AD, Brantigan JW:** The variable screw placement spinal fixation system. Report of a prospective study of 250 patients enrolled in Food and Drug Administration clinical trials. *Spine* 18:1160-1172, 1993.
- 31. Stovall DO Jr, Goodrich A, MacDonald A, et al.** Pedicle screw instrumentation for unstable thoracolumbar fractures. *J South Orthop Assoc.* 5: 165-173, 1996.
- 32. Trivedi JM.** Spinal trauma: therapy-options and outcomes. *Eur J Radiol.* 42: 127-134, 2002.
- 33. Verlaan J J, Diekerhof C H, Buskens E, et al:** Surgical Treatment of Traumatic Fractures of the Thoracic and Lumbar Spine. A Systematic Review of the Literature on Techniques, Complications, and Outcome. *Spine* 29(7):803-814, 2004.
- 34. Verlaan JJ, van Helden WH, Oner FC, et al.** Balloon vertebroplasty with calcium phosphate cement augmentation for direct restoration of traumatic thoracolumbar vertebral fractures. *Spine* 27:543-8, 2002.
- 35. Vornanen MJ, Bostman OM, Myllynen PJ:** Reduction of bone retracted into the spinal canal in thoracolumbar vertebral body compression burst fractures. A prospective randomized study between Harrington rods and two transpedicular devices. *Spine* 20:1699-1703, 1995.
- 36. Wildburger R, Mahring M, Paszicsnyek T, et al.** Dorsal stabilization of thoracolumbar spinal instability: comparison of three different implantation systems. *Arch Orthop Trauma Surg.* 113: 244-247, 1994.
- 37. Wood KB, Wentorf FA, Ogilvie JW, et al:** Torsional rigidity of scoliosis constructs. *Spine* 25: 1893-1898, 2000
- 38. Yahiro MA:** Comprehensive literature review. Pedicle screw fixation devices. *Spine* 19 (Suppl 20):2274S-2278S, 1994.
-