

Role of Surgery in Tuberculosis of Thoracic and Lumbar Spine

**Mohamed Lotfy, Alaa A. Farag, Naser Mossad, Walid A. Badawy, Hossam Ibrahim, Ahmed Saleem, Islam Abou El Fotouh & Ahmed Saleh*

Department of Neurosurgery, Benha University

* Professor of Neurosurgery, Cairo University

ABSTRACT

Objective: To study the neurological and radiological outcomes in patients who underwent surgery for tuberculosis of thoracic and lumbar spine. **Patients and Methods:** We retrospectively reviewed 18 patients with tuberculous spondylitis of thoracic and lumbar spine treated surgically. These patients were treated between January 2004 and April 2006. Patients were assessed clinically, regarding severity of pain and neurological status, and radiologically, regarding the presence of epidural abscess and spinal instability. Nine patients were treated by anterior approach and nine patients were treated by posterolateral approach. All patients were followed up from 6 months to 3 years. **Results:** Eight patients were men and ten patients were women, with ages ranging from 30 to 85 years (mean 49). Persistent back pain was present in all 18 patients and 17 patients had neurological deficit in the form of weakness attributable to the location of their lesion. The neurological status was assessed according to the scoring system of Frankel et al. The thoracic spine was involved in ten patients and lumbar spine in eight patients. Plain X-ray, MRI and occasionally CT and 3D-CT scan confirmed spondylodiscitis. Back pain was fully relieved in seven patients and eleven patients reported improvement compared with their preoperative condition. Neurological deficits were improved at the final follow up examination in 17 patients as defined by the scoring system of Frankel et al. **Conclusion:** Spinal tuberculosis was best treated with appropriate anti-tuberculous chemotherapy and radical debridement surgery when indicated. Surgery is reserved for patients with progressive neurological deficit, spinal instability, drainage of abscess or severe pain despite of anti-tuberculous therapy. Surgical treatment has provided much earlier healing, quicker pain relief, earlier abscess drainage and sinus tract resolution, and a better chance of neurologic recovery, as well as a lesser degree of spinal deformity.

INTRODUCTION

There is an increase in the incidence of tuberculosis all over the world. Tuberculous spondylitis is the most common form of skeletal tuberculosis, comprising approximately 50% of all cases. The incidence of neuro-logical involvement represents 10% of those with spinal tuberculosis⁽¹⁴⁾.

The clinical presentation of tuberculous spondylitis is variable, but symptoms are less severe than in pyogenic infections. Persistent back pain is the most consistent symptoms, generalized malaise, fever, night

sweats and neurological deficit can also be present⁽⁴⁾.

Laboratory studies and plain radiographs offer diagnostic help, but they are non-specific. Magnetic resonance imaging "MRI", specially after intra-venous administration of gadolinium, has high specificity and sensitivity. However, tissue biopsy and culture are the most important to establish a definitive diagnosis⁽¹⁹⁾.

The treatment options for tuberculous spondylitis are chemotherapy and external immobilization or chemotherapy with surgery. Surgical intervention is indicated for patients with progressive neurological deficit, progressive

kyphotic deformity, spinal instability, cold abscess and severe pain. The goals of surgery are to decompress neurological tissue, evacuation of cold abscess with debridement, correct the spinal deformity and maintain stability of the spine. In this study, we spotlighted on the surgical treatment of thoracic and lumbar tuber-culosis.

PATIENTS & METHODS

We retrospectively reviewed 18 patients with tuberculous spondylitis of thoracic and lumbar spine treated surgically. These patients were treated between January 2004 and April 2006. Eight patients were men and ten

patients were women, with ages ranging from 30 to 85 years (mean 49). Patients were assessed clinically, regarding severity of pain and neurological status, and radiologically, regarding the presence of epidural abscess and spinal instability.

Persistent back pain was present in all 18 patients and 17 patients had neurological deficit in the form of weakness attributable to the location of their lesion. The neurological status was assessed according to the scoring system of Frankel et al (table 1). There was one patient with Frankel grade A, four with grade B, eight with grade C, four with grade D and one with grade E.

Table (1) Frankel et al classification

Grade A	Complete motor-sensory deficit below the level of the lesion.
Grade B	Complete motor deficit with sensory sparing.
Grade C	Motor power is <3/5 in majority of affected muscles.
Grade D	Motor power is >3/5 in majority of affected muscles.
Grade E	Normal power.

The thoracic spine was involved in ten patients and lumbar spine in eight patients. Plain antero-posterior (AP) and lateral radio-graphs, MRI and occasionally CT and 3D-CT confirmed spondylodiscitis. Two contiguous vertebrae were involved in eleven patients and the lesion was localized in one vertebra in seven cases. An epidural abscess was seen in 14 patients.

Indications for surgery were: progressive neurological deficit, spinal instability, epidural abscess or severe back pain and/or radicular pain resistant to conservative treatment. Nine patients were treated by anterior approach and nine patients were treated by posterolateral approach. In the anterior approach, one patient was operated by sternotomy, D1&D2 corpectomy & fusion with bone graft. Retroperitoneal approach was done for one patient with L4& L5 corpectomy&

fusion with titanium cage followed by posterior trans-pedicular fixation (Figure1-2). Seven patients were operated upon by thoracotomy & fusion with cage & Z -plate. In the posterolateral approach, eight patients were operated upon by posterolateral decompression and transpedicular screw fixation (Figure 3-4) and one patient by posterolateral decompression only.

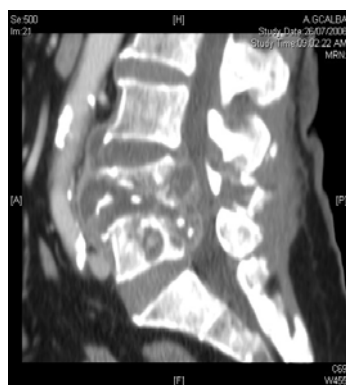Tissue specimens were sent for histopathological examination and cultures. Diagnosis was confirmed through positive histopathological sections; showed langerhans giant cells, granulomatous tissue and caseating necrosis; and PCR.

Anti-tuberculous chemotherapy was begun 6 months before surgery for patients with radiological and laboratory evidence of TB and after surgery for all patients. In addition to the anti-tuberculous chemotherapy,

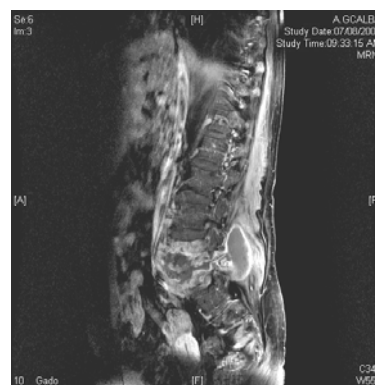intravenous antibiotic drug for 5-7 days was given to all patients after surgery. All patients were mobilized during the first post-operative week with aid of brace. Erythrocyte sedimentation rate (ESR) and C-reactive protein (CRP) were monitored regularly to exclude the presence of active disease process. The postoperative chemotherapy was included isoniazid (300mg per day),

rifampicin (600mg per day) and ethambutol (500mg per day) and lasted 9-12 months.

All patients were followed up from 6 months to 3 years. All patients were evaluated by full clinical examination at 1, 3, 6 and 9 months after surgery. During each follow up visit, plain radiographic studies, ESR and CRP were requested to determine the presence of active disease.

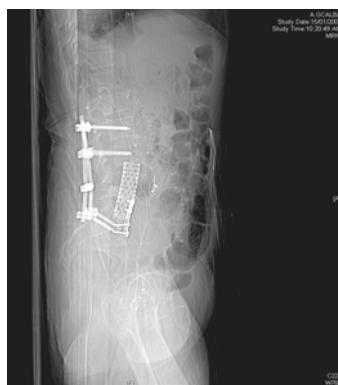

(A)

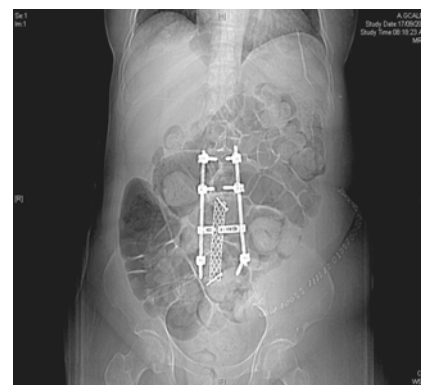


(B)

Fig. (1): Pre-op 3D CT (A) and MRI –T1 with Contrast (B) Showing Destruction of L4 & L5 Vertebral Bodies with Anterior Epidural and Para-Vertebral Abscess



(A)



(B)

Fig. (2): Post-op Plain X-ray Lateral View (A) and A-P View (B) Showing L3 to S1 Anterior Inter-body Arthrodesis and Posterior Transpedicular Screw Fixation.

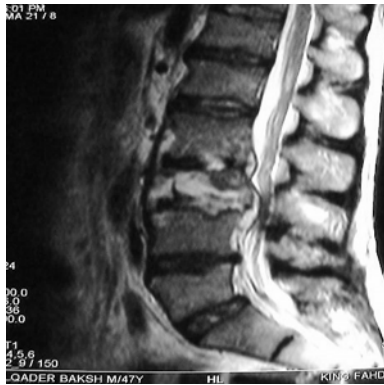

Fig. (3): Pre-op MRI-T2 Showing Destruction of L3 Vertebra with Anterior Epidural Abscess

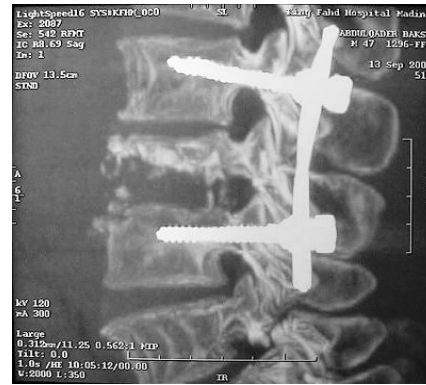


Fig. (4): Post-op 3D CT Showing Transpedicular Screw Fixation

RESULTS

The number of patients reviewed is 18. The age ranges from 30 to 85 years (mean 49 years). Eight patients are male and ten patients are female.

All patients had persistent back pain from 6 months to 2 years (mean 10 months). Neurological deficits assessed according to Frankel et al. classification (Table 1).

We had one patient with grade A, four patients with grade B, eight patients with grade C, four patients with grade D and one patient with grade E.

The thoracic spine was involved in ten cases and lumbar spine in eight cases. Two contiguous vertebrae were involved in eleven patients and the lesion was localized in one vertebra in seven cases. An epidural abscess was seen in 14 cases.

Erythrocyte sedimentation rate was high in all patients ranged from 36-143mm/h. The mean ESR was 79.5mm/h. CRP was high in all patients, the mean value is 3.7mg/dl. Infection control was achieved in all patients and no recurrence was recorded. ESR and CPR were decreased within 6 months in all patients.

Back pain was fully relieved in 7 patients and 11 reported improvement compared with their preoperative condition. Neurological deficits were improved at the final follow up examination in 17 patients as defined by the scoring system of Frankel et al. Four patients of grade B before surgery, had improvement two to grade C and two to grade D. Of the eight with grade C, five had complete recovery to grade E and three had improvement by one level to grade D. Four patients with grade D had complete recovery to grade E. No patient was made worse by surgery.

We had 3 patients with post-operative complications. One patient developed displacement of mesh cage between L3 and S1, and needs re-exploration and reinsertion of the cage. One patient developed atelectasis and resolved with intensive chest physiotherapy. One patient developed superficial wound infection and improved with dressing and antibiotic.

DISCUSSION

Tuberculous spondylitis mainly affects the anterior column of the spine and is more common in patients with compromised immune function and

elderly patients⁽¹⁷⁾. Its clinical presentation is variable, but a high index of suspicion and MRI has led to early diagnosis and initiation of anti-tuberculous chemotherapy⁽¹⁹⁾. Tissue biopsy and culture remain important in securing a definitive diagnosis and should always be obtained before the appropriate medical treatment is initiated⁽⁵⁾.

Tuberculous spondylitis treatment recommendations are not uniform throughout the world. However, surgical debridement and stabilization is indicated in the presence of an epidural abscess, neurological deficit because of compression, structural destruction resulting in instability, or when anti-tuberculous chemotherapy has failed⁽¹⁷⁾.

Although surgical treatment of spinal tuberculosis remains controversial, it has been shown that radical debridement produces best results when compared with other treatment methods. The excellent results from Hong Kong group and the British Medical Council recommended that spinal tuberculosis was best treated with appropriate anti-tuberculous chemotherapy and radical debridement surgery if adequate surgical, anaesthetic, nursing experts and supportive facilities were available. Surgical treatment has provided much earlier healing, quicker pain relief, earlier abscess drainage and sinus tract resolution, and a better chance of neurologic recovery, as well as a lesser degree of spinal deformity than other treatment methods⁽¹⁰⁾.

Metha et al. classified patients into four groups based on radiologic findings. They recommended anterior debridement with strut grafting for lesions that are stable with no kyphotic deformity, posterior instrumentation in addition to the above procedure for global lesions with kyphosis and instability. Trans-pedicular route and

posterior instrument-entation in patients with global lesions who are medically unfit for transthoracic approaches and post-erior decompression only for posterior element disease⁽¹²⁾.

Commonly, anterior debridement with or without posterior instrumentation is used for cases of advanced disease, but more limited approaches may have a role in less severe cases or patients unable to tolerate extensive surgery⁽²⁾.

Posterior approaches include simple laminectomy and debridement for extradural or subdural granulation tissue, in the absence of significant bone collapse⁽³⁾. Posterior instrumentation and fusion alone constitute one kind of treatment for patients with spine tuberculosis. Posterior instrumentation is used as an internal splint to prevent kyphosis⁽⁹⁾. Guven et al reported that in selected cases, single stage posterior instrumentation and fusion with or without transpedicular drainage of an abscess is an important and practical method in patient with kyphosis⁽⁷⁾.

Because anterior approach gives the best access for debridement and stabilization by grafting and facilitates rehabilitation, anterior radical surgery has become the standard operative treatment when surgical intervention is indicated⁽¹¹⁾. Various anterior structural grafting techniques have been used, including autogenous iliac crest graft or rib graft,⁽¹⁶⁾ and femoral or fibular allograft⁽⁶⁾.

The use of a cage and bone grafts instead of a structural bone graft alone allows for more secure, accurate and dependable deformity correction⁽¹⁸⁾. The cage provides a more rigid fixation construct and minimizes the risk of graft subsidence or dislodgement, that are well documented complications when structural bone graft alone is used⁽¹⁸⁾.

A single-stage or two-stage procedure with instrumented post-erior fixation has been recommended as an adjunct to anterior debridement and fusion⁽⁸⁾. Supplementary posterior instrumentation and fusion has greatly improved the outcome, especially in those with involvement of more than two vertebral bodies. Al-Sebai et al performed a one-or two-stage posterior fusion and fixation on 14 patients with progressive deformity, resulting from spinal tuberculosis, following anterior debridement and grafting.

Satisfactory fusion was noted in all patients within a period of 4 to 9 months after surgery⁽¹⁾.

The risk of persistence and recurrence of infection in posterior spinal instrumentation surgery for spinal tuberculosis was studied clinically and microbiologically by Oga et al. The results suggested that posterior instrumentation was not a hazard to spinal tuberculosis infection when combined with radical debridement and intensive anti-tuberculous chemotherapy. However, the combined procedure may be associated with prolonged operating time, greater blood loss, increased peri-operative complications and mortality⁽¹⁵⁾

CONCLUSION

Spinal tuberculosis was best treated with appropriate anti-tuberculous chemotherapy and radical debridement surgery when indicated. Surgery is reserved for patients with progressive neurological deficit, spinal instability, drainage of abscess or severe pain despite of anti-tuberculous therapy. Surgical treatment has provided much earlier healing, quicker pain relief, earlier abscess drainage and sinus tract resolution, and a better chance of neurologic recovery, as well as a lesser degree of spinal deformity.

Anterior approach gives the best access for debridement and stabilization by grafting and facilitates rehabilitation.

Our choice of surgical procedure depends on several factors, medical status of the patient, neurological status and degree of vertebral involvement.

REFERENCES

1. **Al-Sebai MW, Al-Khawashki H and Al-Arabi K.:** Operative treatment of progressive deformity in spinal tuberculosis. *Int Orthop* 2001; 25:322-5.
2. **Andrews N, Swanson MD, Ioannis P, Pappou MD, Frank P, Camisa MD and Federico P:** Girardi MD. Chronic infection of the spine. *Clin orthop and relat res.* 2006; 444: 100-106
3. **Ari G, Chacko Mch, Ranjithk, Moorthy and Mathew J Chandy Mch.:** The transpedicular approach in the management of thoracic spine tuberculosis. *Spine.* 2004; 29:363-367
4. **Calderone RR, Larsen JM:** Overview and classification of spinal infections. *Orthop Clin North Am.* 1996; 27:1-8.
5. **Christodoulou A, Zidrou C, Savvidou OD, Givissis P, Apostolou T, Mavrogenis AF, Papagelopoulos PJ and Pournaras J.** Percutaneous Harlow: Wood needle biopsy of the spine: A retrospective analysis of 238 spinal lesions. *Orthopedics.* 2005; 28:784-789.
6. **Govender S.:** The outcome of all grafts and anterior instrumentation in spinal tuberculosis. *Clinorthop,* 2002; 398 : 60-66
7. **Guveno, Kumano K, Yalcins, et al.:** A single stage posterior approach and rigid fixation for preventing kyphosis in the

- treatment of spinal tuberculosis. spine, 1994;19:1093-1043
8. **Klockner CK and Valencia R:** Sagittal alignment after anterior debridement and fusion with or without additional posterior instrumentation in the treatment of pyogenic and tuber-culous spondylodiscitis. Spine 2003; 28: 1036 - 42.
 9. **Lee TC, Luk Yans LC and Huong HY.:** Tranpedicular instrumentation as an adjunct in the treatment of thoracolumbar spine tuberculosis with early stage bone destruction. J neurosurgery. 1999; 91 :163-169
 10. **Li-Yang Dai MD, PhD, Lei-Jiang, MD, MSci, Wei Wang, MD and Yi-Min Cui, MD, MSci:** Single-stage Anterior Autogenous Bone Grafting and Instrumentation in the Surgical Management of Spinal Tuberculosis. Spine. 2005; 30 : 2342 - 2349.
 11. **Luk KDK.:** Tuberculosis of the spine in the new millennium. Eur Spine J 1999; 81:338-45.
 12. **Mehtajs and Bhojraj SY:** Tuberculosis of the thoracic spine. J Bone Joint Surg. 2001; 83:859-863
 13. **Moon MS, Hay KY, San DH, Moon JL, Moon YW and Chung JH:** Potts paraplegia, 67cases. Clin Orthop and relat res. 1996; 323:122-128
 14. **Murat Bezer, MD, Faith Kucukdurmaz, MD, Nuri Aydin, MD, Baris Kocaoglu, MD and Osman Guven:** Tuberculous Spondylitis of the lumbosacral region. Spinal Discord Tech. 2005; 18 :425-429
 15. **Oga M, Arizono T, Takasita M and Sugioka Y.** Evaluation of the risk of instrumentation as a foreign body in spinal tuberculosis: Clinical and biologic study. Spine. 1993; 18 : 1890 - 1894.
 16. **Rajasekaran S and Soundarapandian S.:** Progression of kyphosis in tuberculosis of the spine treated by anterior arthrodesis. J Bone joint Surg Am 1989;71:1314-23.
 17. **Shinkel C, Gottwald M and Andress H-J:** Surgical treatment of spondylodiscitis. Surg Infect. 2003; 4: 387-391.
 18. **Sundararaj GD, Behera S, Ravi V et al.:** Role of posterior stabilization in the management of tuberculosis of the dorsal and lumbar spine. J Bone joint Surg Br 2003; 85 :100-6.
 19. **Tay BK-B, Dekey J and Hu S.:** Spinal infections. J Am Acad Orthop Surg. 2002; 10:188-197.
-

